

## Morphology of ulnar nerve in axilla & arm & its variations

<sup>1</sup>Dr. Neelam Sinha, <sup>2</sup>Dr. Sanjay Kumar Sinha, <sup>3</sup> Dr. Ramji Prasad Singh

<sup>1</sup> Assistant professor, department of Anatomy, Nalanda Medical College and Hospital, Patna, Bihar, India

<sup>2</sup> MS General Surgery G.I. & Laparoscopic Surgeon

<sup>3</sup> Professor & HOD, Department of Anatomy, Nalanda Medical College and Hospital, Patna, Bihar, India

### Abstract

The ulnar nerve is the second commonest to involve in entrapment neuropathy. These variations gain importance during surgical procedures of shoulder & elbow, when the presence of an unexpected variation can lead to iatrogenic damage. Hence this study is planned with the aim to find the variation on the ulnar nerve.

The study was planned on total 20 embalmed human cadavers of both the sexes. The cadavers are of received from Department of Anatomy Nalanda Medical College & Hospital. The upper limb of the specimens was dissected as per the guidelines in the Cunningham Practical Manual.

In the present study the presence of the ulnar nerve is observed in all specimens. The source of origin is observed from medial cord of the brachial plexus in in 95% of cases and from lateral root of the median nerve in 5% of cases. The level of origin is seen from the tip of the acromion in 95% of cases and from distal to the tip of the acromion process in 5% of cases. The Course of ulnar nerve is observed medial to axillary & brachial artery in 95% of cases and anterior to the third part of the axillary artery and brachial artery in 5% of cases.

The differences in ulnar nerve can also responsible for arising difficulty in diagnosis of neurological syndromes. Worthy acquaintance of the distribution and variations of the ulnar nerve and its possible communications with the median nerve are appreciated in trauma to the upper limb.

**Keywords:** ulnar nerve, axilla, arm, median nerve, etc.

### Introduction

In human anatomy, the ulnar nerve is a nerve that runs near the ulna bone. The ulnar collateral ligament of elbow joint is in relation with the ulnar nerve. The nerve is the largest unprotected nerve in the human body (meaning unprotected by muscle or bone), so injury is common. This nerve is directly connected to the little finger, and the adjacent half of the ring finger, innervating the palmar side of these fingers, including both front and back of the tips, perhaps as far back as the fingernail beds.

This nerve can cause an electric shock-like sensation by striking the medial epicondyle of the humerus from posteriorly, or inferiorly with the elbow flexed. The ulnar nerve is trapped between the bone and the overlying skin at this point. This is commonly referred to as bumping one's "funny bone". This name is thought to be a pun, based on the sound resemblance between the name of the bone of the upper arm, the "humerus" and the word "humorous" [1]. Alternatively, according to the Oxford English Dictionary it may refer to "the peculiar sensation experienced when it is struck" [2].

The ulnar nerve originates from the C8-T1 nerve roots (and occasionally carries C7 fibres) which form part of the medial cord of the brachial plexus, and descends on the posteromedial aspect of the humerus. It runs inferior to the posteromedial aspects of the humerus, passing behind the medial epicondyle (in the cubital tunnel) at the elbow where it is exposed for several centimetres.

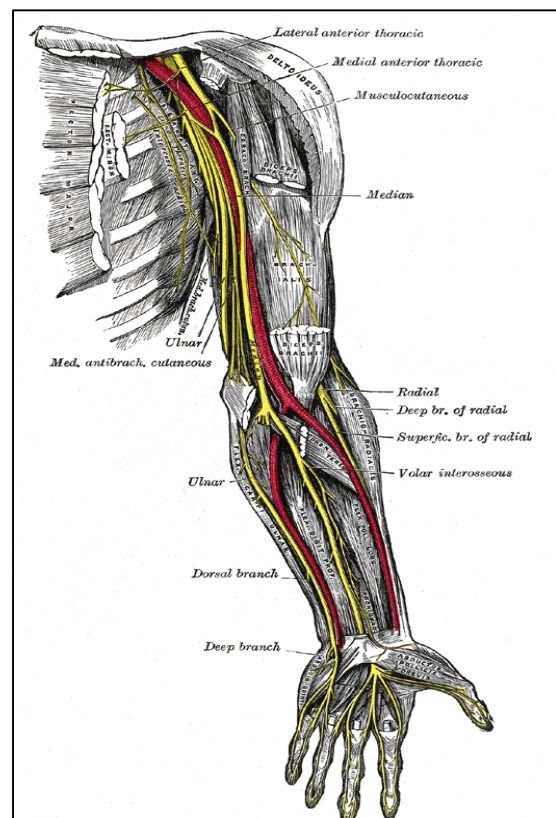


Fig 1

It enters the anterior (flexor) compartment of the forearm between the humeral and ulnar heads of flexor carpi ulnaris, lying under the aponeurosis of flexor carpi ulnaris alongside the ulna. There it supplies one and a half muscles (flexor carpi ulnaris and the medial half of flexor digitorum profundus) and courses with the ulnar artery, travelling inferiorly with it deep to the flexor carpi ulnaris muscle.

The ulnar nerve is derived from the brachial plexus. It is a continuation of the medial cord, containing fibres from spinal roots C8 and T1.

After arising from the brachial plexus, the ulnar nerve descends down the medial side of the upper arm. At the elbow, it passes posterior to the medial epicondyle of the humerus, entering the forearm. At the medial epicondyle, the nerve is easily palpable and vulnerable to injury.

In the forearm, the ulnar nerve pierces the two heads of the flexor carpi ulnaris, and travels alongside the ulna. Three branches arise in the forearm:

- **Muscular branch:** innervates some muscles in the anterior compartment of the forearm.
- **Palmar cutaneous branch:** innervates the skin of the medial half of the palm.
- **Dorsal cutaneous branch:** innervates the skin of the medial 1 and 1/2 fingers, and the associated palm area.

*(The functions of these nerves are explored in more detail later in the article).*

At the wrist, the ulnar nerve travels superficially to the flexor

retinaculum. It enters the hand via the ulnar canal (or Guyon’s canal). In the hand the nerve terminates by giving rise to superficial and deep branches [3].

The ulnar nerve is the second commonest to involve in entrapment neuropathy. These variations gain importance during surgical procedures of shoulder & elbow, when the presence of an unexpected variation can lead to iatrogenic damage. Hence this study is planned with the aim to find the variation on the ulnar nerve.

**Methodology**

The study was planned on total 20 embalmed human cadavers of both the sexes. The cadavers are of received from Department of Anatomy Nalanda Medical College & Hospital. The upper limb of the specimens was dissected as per the guidelines in the Cunningham Practical Manual.

The various observations were noted. The existence or lack of ulnar nerve is reported. Source of origin of ulnar nerve, its level of origin recorded with tip of acromion as bony point of reference, relation with neighbouring structures & its course & distribution till cubital fossa were perceived. All its branches were identified. Intercommunication between the ulnar nerve and median nerve were observed.

**Results and Discussion**

Following are the observations were noted from the selected specimens.

**Table 1**

Parameter	Observation	Percentage
Presence of ulnar nerve	In all specimens: 20 cases	100%
Source of origin	From medial cord of the brachial plexus: in 19 cases	95%
	From lateral root of the median nerve: in 1 cases	5%
Level of origin	From the tip of the acromion: in 19 cases	95%
	From distal to the tip of the acromion process: 1 case	5%
Course of ulnar nerve	Normal course, i.e. medial to axillary & brachial artery: 19 Cases	95%
	Anterior to the third part of the axillary artery and brachial artery: 1 Case	5%

In the present study the presence of the ulnar nerve is observed in all specimens. The source of origin is observed from medial cord of the brachial plexus in in 95% of cases and from lateral root of the median nerve in 5% of cases. The level of origin is seen from the tip of the acromion in 95% of cases and from distal to the tip of the acromion process in 5% of cases. The Course of ulnar nerve is observed medial to axillary & brachial artery in 95% of cases and anterior to the third part of the axillary artery and brachial artery in 5% of cases.

Chaware *et al* reported that the anterior division of the middle trunk and lower trunk joined to form ulnar nerve proper. Thus root value of ulnar nerve was C7, C8, T1 [4]. Gonclaves *et al* described about the origin of the ulnar nerve from the posterior cord of the brachial plexus [5].

Sachdeva & Singla reported that anterior division of C8, T1 formed medial cord, which gives rise to the medial root of the median nerve and the ulnar nerve normally. Medial cord gave rise to medial root of the median and the medial cutaneous nerve of the forearm. Later both the roots of the median nerve united with each other. Then ulnar nerve arose 4cm distally from the medial root of median, and continued as ulnar nerve proper and median nerve proper. Rest of the course of the ulnar nerve was normal [6].

Ramchandran *et al* reported that ulnar nerve also received contribution from lateral root of median nerve [7].

The differences in ulnar nerve can also be responsible for arising difficulty in diagnosis of neurological syndromes. Worthy acquaintance of the distribution and variations of the ulnar nerve and its possible communications with the median nerve are appreciated in trauma to the upper limb. The responsiveness of these differences along the normal pattern are helpful for the interventional radiologists, orthopaedicians and neurologists in preventing untoward iatrogenic injury to the ulnar nerve during radiological procedures or operating on fractured patients or diagnostic therapy.

**References**

1. Hendrickson, Robert A. The Facts on File Encyclopedia of Word and Phrase Origins (Facts on File Writer’s Library). New York: Checkmark Books. 281. ISBN 0-8160-5992-6.
2. Welcome to the new OED Online : Oxford English Dictionary. Dictionary.oed.com. Retrieved 2012-03-20.
3. <http://teachmeanatomy.info/upper-limb/nerves/the-ulnar-nerve>.

4. Chaware PN, Ughade JM, Pandit SV, Maske GL. Variant branches of brachial plexus – a case report. *International Journal of Anatomical Variations*, 2012; 5:5-7.
5. Goncalves J, Duparc F, Auquit- Auckbur I, Milliez PY. Constitutional anomalies of the terminal branches of the brachial plexus in the axial and the brachial regions. Results of 42 cases and review of literature. *Ann Chir Plast Esthet*. 2002; 47(1):30-35.
6. Sachdeva K, Singla RK. An unusual origin of an ulnar nerve from a median nerve – a case report; *Journal of Clinical and Diagnostic Research*. 2011; 5(6):1270-1271.
7. Ramachandran K, Kanakasabapathy I, Holla SJ. Multiple variations involving all the terminal branches of the brachial plexus and the axillary artery – a case report. *Eur J Anat*. 2006; 10(3):61- 66.